

The role of bis4-(4'-hydroxy-3'-methoxy benzylidene aminophenyl) telluride in protecting rat's testis from sodium nitrite induced damage

Shaker A.N. AL-Jadaan^{*}, Mohammed A. Al-Diwan^{}, Haithem J. Kadhum^{***}**

^{*}Department of Pharmaceutical Chemistry, College of Pharmacy, University of Basrah, Iraq,

^{**}Department of Physiology, College of Veterinary Medicine, University of Basrah, Iraq, ^{***}Department of Physiology, College of Medicine, University of Basrah, Iraq.

Corresponding author E-mail: shakeraljadaan@yahoo.com

Mobile: +9647811111180

ABSTRACTS - Oxidative stress is involved in the pathogenesis of infertility. A considerable interest in organotellurium compounds as potential antioxidants in living systems. The aim from this study is to investigate the role of a novel organotellurium compound, [4-(4'-hydroxy-3'-methoxy benzylidene amino phenyl) telluride], in protecting testicular rats from oxidative stress induced by NaNO₂. Forty adults male rats divided into 5 equal groups are used in this study. The 1st group is control, the 2nd group treated with 0.2% NaNO₂ in the drinking water, the 3rd and 4th groups given the novel compound orally in addition to the NaNO₂ at a dose of 11 and 5.5mg/kg respectively, whereas the last group given the novel compound only (11mg/kg). Semen fluid analysis, histological study of the testes was carried out after the experimental period (1 month). Marked histopathological changes and significant reduction in sperm count, motility and viability has been observed in NaNO₂ group. These changes are improved by treatment with the novel compound. It can be concluded that the gonad protective effect of the organotellurium compound, 4-(4'-hydroxy-3'-methoxy benzylidene amino phenyl) telluride, against NaNO₂ induced testicular damage may be attributed to its antioxidant activity.

Index Terms: Organotellurium compound, NaNO₂, rat's testes

1-INTRODUCTION

Disturbance in the equilibrium between pro-oxidant and antioxidant molecules is often referred to as oxidative stress. In humans, oxidative stress is thought to be involved in the development of a wide range of diseases including cancer [1], Parkinson's disease [2], Alzheimer's disease [3], cardiovascular disease [4], and infertility [5].

Sodium nitrite (NaNO_2) is widely used in food and drug industries as a preservative [6] and in medicine as antidote for cyanide poisoning [7]. Sodium nitrite in blood is highly reactive with hemoglobin and thus affecting hematopoiesis. A major concern considering the toxicology of sodium nitrite is the induction of methemoglobinemia; a condition in which there is a reduction in oxygen transport ability of hemoglobin [8].

The role of oxidative stress as a causative agent of infertility has been well studied in human. It has been

found that in patients with varicocele, the MDA increased, whereas superoxide dismutase (SOD), glutathione peroxidase (GPx) and catalase are decreased in seminal fluid. These changes are associated with decreased sperm count, motility and increased percentage of abnormal sperms [9]. Decreased sperm count, increased abnormally shaped sperm and decreased serum testosterone are well known consequences of high altitude hypoxia [10]. Hydrogen peroxide induced oxidative stress in rat resulted in testicular degeneration and significant reduction in sperm viability, motility, count and rate of normal sperm [11]. Moreover, animal experimental data have shown reproductive toxicity associated with exposure to high levels of nitrate or nitrite [12]. Abnormalities in sperm-head and infertility in nitrite treated mice has been reported [13]. Concomitant administration of imipramine and nitrite resulted in

infertility or delayed impregnation in female mice [14].

Nitrite may change the testicular oxidative status and may play a role in testicular dysfunction that causes infertility. Akintunde *et al.* [15] reported significant histopathological changes in seminiferous tubules of nitrite treated rats. These changes are focal areas of lost germ cells, hyperplasia of Leydig cells and arrest of spermatogenesis while there was no evidence of spermatogenesis at high nitrite dose. Acute nitrite intoxication in rats resulted in disorganization of seminiferous epithelium and assemblance of undifferentiated germ cells in the luminal area of the tubules [16].

The use of antioxidants as dietary supplements has been investigated in various diseases such as hypertension [17], cancer [18], infertility [19] and neurodegenerative diseases [20]. Development of novel and potent antioxidants plays an important role in

targeting therapeutic intervention in neurodegenerative disorders such as Alzheimer disease in which oxidative stress has been implicated [21]. There has been a considerable interest in organotellurium compounds as potential antioxidants in living systems. The chemistry of tellurium is similar to that of sulfur and selenium. More importantly, tellurium is more nucleophilic than sulfur, and thus molecules containing tellurium can react faster with electrophilic compounds such as free radicals [22]. The study designed to investigate the role of the novel organotellurium compound in protecting testicular rats from oxidative stress induced by sodium nitrite administration.

2-MATERIALS AND METHODS

2-1 Chemicals:

Sodium nitrite (NaNO_2) was applied as a freshly prepared solution and given in a dose of 0.2% (2 g/L) in the drinking water. R_2Te , organotellurium compound, bis [4-

(4'-hydroxy-3'-methoxybenzylideneaminophenyl)]telluride has been synthesized and characterized and its LD_{50} that determined by oral route in adults' male albino rats is 219mg/kg body weight [23, 24]. Bis[4-(4'-hydroxy-3'-methoxybenzylideneaminophenyl)]telluride was administered as suspension in corn oil by gavages at a doses of 5.5 and 11mg/kg corresponding to 1/20 and 1/40 of its LD_{50} respectively [25, 26].

2-2-Experimental animals:

Forty male adults' albino rats (*Rattus norvegicus*) of about 5 months age and weighting about 300 ± 25 g were used in this experiment. Rats were kept under standard environmental conditions at temperature 24-28°C and 12 hours photoperiod. They were acclimatized for 2 weeks before the start of the experiment and housed in polyethylene cages with wire mesh, 2 rats per cage. They fed standard rat

pellet and fresh clean water was provided at libitum.

2-3-Experimental design:

The rats are divided randomly into 5 equal groups (8 rats in each group) and treated for 1 month as following:

1. Control group: In which rats were given corn oil orally by gavages (0.2 ml/day).
2. $NaNO_2$ group: In which rats were given corn oil orally by gavages (0.2 ml/day) and 0.2% $NaNO_2$ in the drinking water [27,28].
3. R_2Te (11mg/kg) and $NaNO_2$ group: In which rats were given 11mg/kg of R_2Te (dose corresponding to 1/20 of R_2Te LD_{50}) in 0.2ml corn oil by oral gavages daily and 0.2% $NaNO_2$ in the drinking water.
4. R_2Te (5.5mg/kg) and $NaNO_2$ group: In which rats were given 5.5mg/kg of R_2Te (dose corresponding to 1/40 of R_2Te LD_{50}) in 0.2ml corn oil by oral

gavages daily and 0.2% NaNO₂ in the drinking water.

5. R₂Te group: In which rats were given 11mg/kg of R₂Te (dose corresponding to 1/20 of R₂Te LD₅₀) in 0.2ml corn oil by oral gavages daily.

Rats were sacrificed, after light chloroform anesthesia, at the end of experimental period (1 month). The tail of the epididymis was kept in glass Petri dish containing 5 ml normal saline and used for semen analysis. Sperms count and viability were determined according to method of Evan and Maxwell [29]. Individual sperm motility is measured depending upon the graduation basis suggested by Chemineau *et al*[30]. Testes (right) were removed and fixed by 10% formalin for histological examination.

2-4 Statistical analysis

Computerized SPSS (Statistical Package for Social Sciences) (V.13) program were used for analysis of results. The data were expressed as

mean \pm standard deviation (mean \pm SD). Least significant difference test (LSD) was used to test the difference between means (groups); $P \leq 0.05$ was considered significant [31].

3-RESULTS

3-1-Effect of NaNO₂ and R₂Te on sperm count, motility and viability

Data in the present study showed a significant reduction ($P < 0.05$) in sperm count and motility and a significant increase ($P < 0.05$) in percentage of dead sperm in rats given sodium nitrite compared with control.

The deleterious effects of sodium nitrite are ameliorated in rats treated by R₂Te in either low (5.5mg/kg) or high dose (11mg/kg) and values of sperm count, motility and viability approach the values in the control group.

It is clear that separate administration of R₂Te do not adversely affect the semen fluid as compared with the control (Table: 1)

Table (1) Effect of NaNO₂ and R₂Te sperm count, motility and viability.

Group	Sperm count (10 ⁶ /ml)	Motility (%)	Dead sperm (%)
Control	824.3±44 a	78.1±7.03 a	15.6±1.9 b
NaNO ₂ (0.2%)	644.2±129 b	63.1±11.3 b	19.1±3.0 a
R ₂ Te (11mg/kg) & NaNO ₂ (0.2%)	827.9103 a	76.8±7.9 a	16.8±2.2 b
R ₂ Te (5.5mg/kg) & NaNO ₂ (0.2%)	818.8±130 a	74.6±9.0 a	16.6±1.4 b
R ₂ Te (11mg/kg)	845.8±159 a	79.4±12.1 a	15.8±1.5 b
LSD	174.6	11.5	2.4

Data are expressed as means ± SD (n=8).

Different letters indicate significant difference at (P≤0.05).

3-2-Effect of NaNO₂ and R₂Te on testis histology

In control group, the testes showed normal structure of somniferous tubules and normal spermatogenesis and supporting cells (Figure 1). Treatment with sodium nitrite resulted in disorganization of

germinal epithelium, impaired spermatogenesis, widening and congestion of interstitial space (Figure 2). Sodium nitrite induced histological changes are obliterated by treatment with R₂Te (Figure 3 and 4). No apparent changes in testes were associated with separate administration of R₂Te (Figure 5).

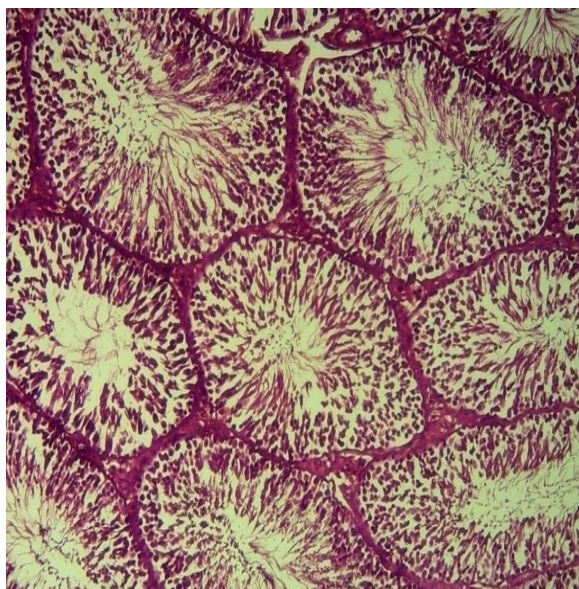


Figure 1: Section of testis of control rat showing normal appearance of the seminiferous tubules and spermatogenesis. H&E

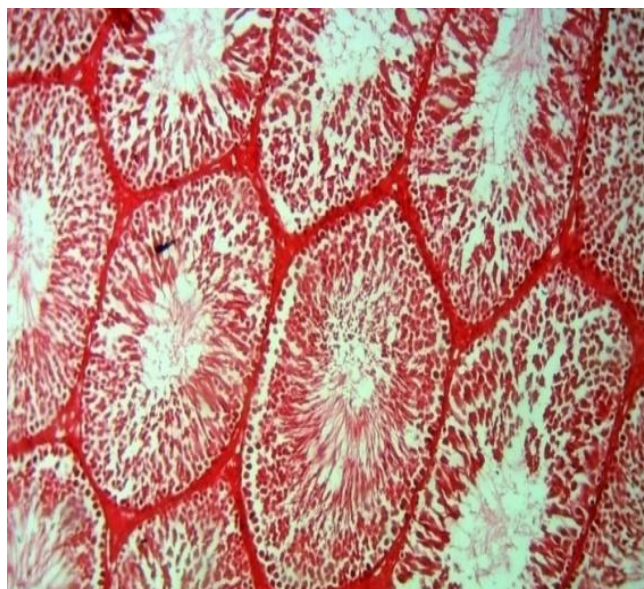


Figure 3: Section of testis of rat treated with NaNO_2 and R_2Te (11mg/kg) showing nearly normal appearance. H&E x100.

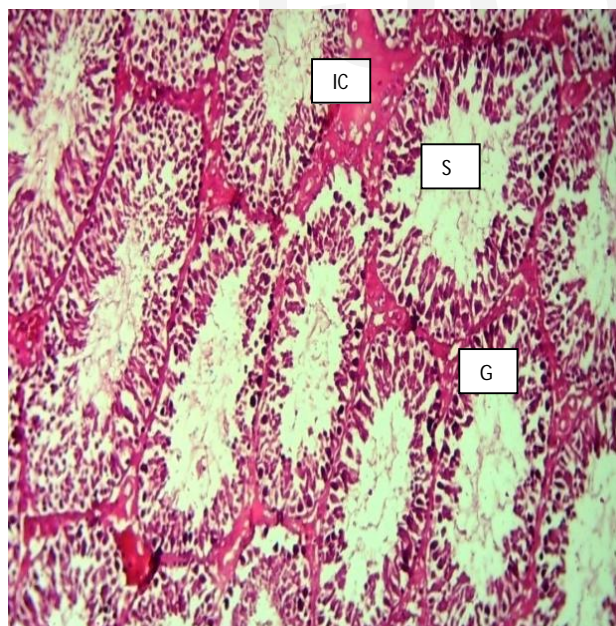


Figure 2: Section of testis of rat treated with NaNO_2 showing disorganization of germinal epithelium (G), incomplete spermatogenesis (S),

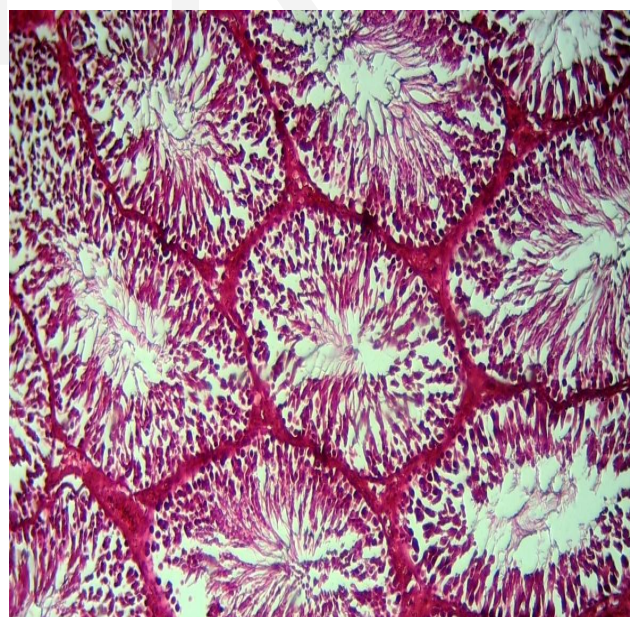


Figure 4: Section of testis of rat treated with NaNO_2 and R_2Te (5.5mg/kg) showing nearly normal appearance. H&E x100.

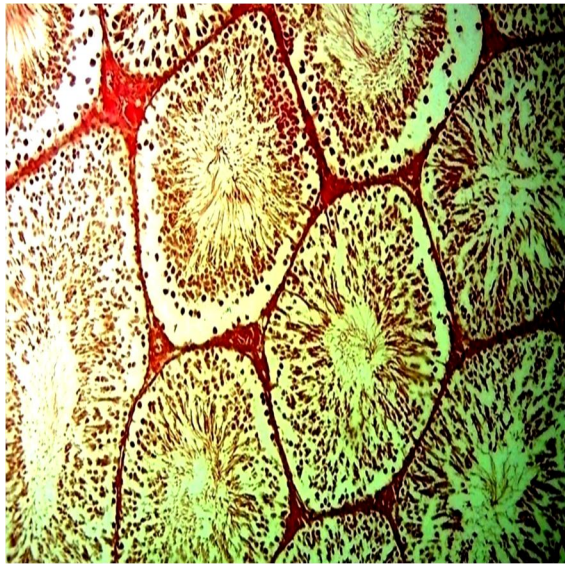


Figure 5: Section of testis of rat treated by R_2Te (11mg/kg) showing nearly normal appearance. H&E x100.

4-DISCUSSION

The results of this study showed a reduction in sperm count, motility and viability of $NaNO_2$ treated rats compared with control (Table 1). The obtained results are in agreement with the results of Pavlova *et al.* [16]. Oxidative stress has been implicated in the pathogenesis of infertility in human [9]. Testicular degeneration with consequent reduction in sperm viability, motility and count has been observed in rats exposed to oxidative stress [11]. The resulting hypoxia

from nitrite induced methemoglobinemia may contribute to the adverse effects of sodium nitrite on sperm quality and quantity. High altitude hypoxia leads to degeneration of the germinal epithelium and spermatogenic arrest in rhesus monkeys [32] and inhibition of spermatogenesis in rats [33]. In addition to that, the effects of chronic hypobaric hypoxia on spermatogenesis may be partially related to changes in the hypophysis-gonadal axis, as FSH rises initially due to spermatogenic damage [34].

It can be concluded that the effects of sodium nitrite on spermatogenesis in this study may be attributed to nitrite induced oxidative stress and hypoxia or disturbances in hypothalamic-pituitary-gonadal axis. The ability of the novel compound, bis4-(4'-hydroxy-3'-methoxybenzylidene amino phenyl) telluride, in modulating the adverse effects produced by sodium nitrite on sperm count, motility and viability may be

attributed to its antioxidant activity and free radical scavenging activity thus reducing the effects of nitrite-induced oxidative stress and hypoxia on somniferous tubules [23].

In this study, various histopathological changes have been observed in testes of sodium nitrite treated rats. The changes observed includes: disorganization of germinal epithelium, impaired spermatogenesis, widening and congestion of interstitial space (Figure 2). The results are in agreement with the results observed by Akintunde *et al.*[15].

A link between NO and an increase in lipid per oxidation products (MDA) has been observed in human varicocele patients [35] and in rats with experimental varicocele [36]. This suggests a role for per oxinitrites in the oxidative stress of varicocele. Moreover, hypoxia induced oxidative damage to male rat reproductive organs and decreased spermatogenesis function [34, 37].

Furthermore, the decrease in spermatogenesis may be attributed to increased temperature secondary to increased blood vessels in the testicular interstitium[38].

In this study, it has been found that the novel compound, bis 4-(4'-hydroxy-3'-methoxybenzylidene-aminophenyl) telluride was effective in preventing the occurrence of sodium nitrite-induced histopathological changes in rat testes (Figure: 3 and 4). The protective effect of this new compound may be attributed to its free radical scavenging activity, thus reducing nitrite induced oxidative stress and damage to rat male reproductive organs. Inhibition of nitrite induced methemoglobinemia and hypoxia by the new compound could be another contributing factor to its protective effect against sodium nitrite-induced rat testicular damage [23].

REFERENCES

- [1] Halliwell B. Oxidative stress and cancer: have we moved forward? *Biochem. J.*, 40, 1 (2007).
- [2] Valko M, Leibfritz D, Moncol J, Cronin MT, Mazur M, Telser J. Free radicals and antioxidants in normal physiological functions and human disease. *Int J Biochem Cell Biol.*, 39, 1 (2007).
- [3] Pohanka M. Alzheimer's disease and oxidative stress: a review. *Curr. Med Chem.*, 21, 3 (2013).
- [4] Van Gaal LF, Mertens IL, De Block CE. Mechanisms linking obesity with cardiovascular disease. *Nature*, 444, 7121 (2006).
- [5] Makker K, Agarwal A, Sharm R. Oxidative stress and male infertility. *Indian J Med Res.*, 129, 4 (2009).
- [6] Sindelar JJ, Milkowski AL. Human safety controversies surrounding nitrate and nitrite in the diet. *Nitric oxide*, 25, 4 (2012).
- [7] Bhattacharya R. Therapeutic efficacy of sodium nitrite and 4-dimethylaminophenol or hydroxylamine co-administration against cyanide poisoning in rats. *Hum Exp Toxicol.*, 14, 1 (1995).
- [8] Poberezkina NB, Zadorina OV, Andriushchenko PI, Khmel'evskii V. The role of peroxidation processes and antioxidant protection in nitrite-induced hypoxia and its correction with vitamins. *Ukr Bio khim Zh.*, 64, 6 (1992).
- [9] Tawadrous GA, Aziz AA, Mostafa T. Seminal soluble fas relationship with oxidative stress in infertile men with varicocele. *Urology*, 82, 4 (2013).
- [10] Okumura A, Fuse H, Kawauchi Y, Mizuno I, Akashi T. Changes in male reproductive function after high altitude mountaineering. *High Alt Med Biol.*, 4, 3 (2003).

- [11] Rahim SM, Taha EM, Mubark ZM, Aziz SS, Simon KD, Mazlan AG. Protective effect of *Cymbopogon citratus* on hydrogen peroxide-induced oxidative stress in the reproductive system of male rats. *Syst Biol Reprod Med.*, 59, 6 (2013).
- [12] Fan AM, Steinberg VE. Health implications of nitrate and nitrite in drinking water: an update on methemoglobinemia occurrence and reproductive and developmental toxicity. *Regul Toxicol Pharmacol.*, 23, 1 (1996).
- [13] Alavantić D, Sunjevarić I, Pecevski J, Bozin D, Cerović G. In vivo genotoxicity of nitrates and nitrites in germ cells of male mice. I. Evidence for gonadal exposure and lack of heritable effects. *Mutat Res.*, 204, 4 (1988).
- [14] Anderson LM, Giner-Sorolla A, Ebeling D. Effects of imipramine, nitrite, and dimethyl nitrosamine on reproduction in mice. *Res Commun Chem Pathol Pharmacol.*, 9, 2 (1978).
- [15] Akintunde OW, Adefule AK, Kehinde B. Some adverse effects of nitrite on oxidative status and histological structure of adult male wistar rats' testes. *AJRC.*, 2, 9 (2014).
- [16] Pavlova E, Dimova D, Petrova E, Gluhcheva Y, Atanassova N. Changes in rat testes and sperm count after acute treatment with sodium nitrite. *Bulgarian Journal of Agricultural Science*, 19, 2 (2013).
- [17] Baradaran A, Nasri H, Rafieian-Kopaei M. Oxidative stress and hypertension: Possibility of hypertension therapy with antioxidants. *J Res Med Sci.*, 19, 4 (2014).
- [18] Jiang R, Sun L, Wang Y, Liu J, Liu X, Feng H, Zhao D. Chemical composition, and cytotoxic, antioxidant and antibacterial activities of the essential oil from

- ginseng leaves. *Nat Prod Commun.*, 9, 6 (2014).
- [19] Sohrabipour S, Jafari A, Kamalinejad M, Sarrafnejd A, Shahrestany T, Sadeghipour HR. The role of flaxseed and vitamin E on oxidative stress in prepubertal rats with experimental varicocele: An experimental study. *Iran J Reprod Med.*, 11, 6 (2013).
- [20] Akanmu MA, Atunwa SA, Ibrahim BO, Lamidi OF, Adam PA, et al. Neuro pharmacological effects of Nigerian honey in mice. *Afr J Tradit Complement Altern Med.*, 8, 3 (2011).
- [21] Butterfield DA, Kanski J. Brain protein oxidation in age-related neurodegenerative disorders that are associated with aggregated proteins. *Mech Ageing Dev.*, 122, 9 (2001).
- [22] Sies H, Arteel GE. Interaction of per oxynitrite with seleno proteins and glutathione peroxidase mimics. *Free Radic Biol Med.*, 28, 10 (2000).
- [23] Kadhum HJ, Al-Dewan MA, AL-Jadaan SA. Synthesis, characterization and antioxidant activity of bis [4-(4'-hydroxy-3'-methoxy bezylidine amino phenyl)] telluride. *Bas J Vet Res.*, 1, 2 (2014).
- [24] Kadhum HJ, Al-Dewan MA, AL-Jadaan SA. Hepatoprotective and hypolipidemic effects of bis [4-(4'-hydroxy-3'-methoxy bezylidine aminophenyl)] telluride (R_2Te) against sodium nitrite intoxication in male albino rats. *Bas J Vet Res.*, 14, 1 (2015).
- [25] Shalaby MA, El Zorba HY, Ziada RM. Reproductive toxicity of methomyl insecticide in male rats and protective effect of folic acid. *Food Chem. Toxicol.*, 48, 11 (2010).
- [26] Ibrahim NM, Eweis EA, El-Beltagi HS, Abdel-Mobdy YE. Effect of lead acetate toxicity on experimental male albino rat. *Asian Pac J Trop Biomed.*, 2, 1 (2012).

- [27] Nyakas C, Markel E, Bohus B, Schuurman T, Luiten PGM. Protective effect of calcium antagonist nimodipine on discrimination learning deficits and impaired retention behaviour caused by prenatal nitrite exposure in rats. *Behav Brain Res.*, 38, 1 (1990).
- [28] Krishnan SN, Senthil A, Kumar PS, Mohideen S, Delhiraj H. Free radical scavenging activity of *Evolvulus sinoides* on hypoxia induced neuro degeneration. *IJRAP.*, 2, 1 (2011).
- [29] Evan G and Maxwell WMC. *Salamones artificial insemination of sheep and goat*. Butter worth. Sydney, Australia; pp.1-94 (1987).
- [30] Chemineau P, Cagnie Y, Gue'rin Y, Orgeur P, Vallet JC. *Training manual on artificial insemination in sheep and goat*. FAO, Rome; (1991).
- [31] SPSS Statistical Packages for the Social Sciences. Statistical software for windows version 13.0 Microsoft. SPSS®, Chicago, IL, USA: (2001).
- [32] Saxena DK. Effect of hypoxia by intermittent altitude exposure on semen characteristics and testicular morphology of male rhesus monkeys. *Int J Biometeorol.*, 38, 3(1995).
- [33] Liao W, Cai M, Chen J, Huang J, Liu F, Jiang C, Gao Y. Hypobaric hypoxia causes deleterious effects on spermatogenesis in rats. *Reproduction*, 139, 6(2010).
- [34] Farias JG, Bustos-Obregon E, Tapia PJ, Gutierrez E, Zepeda A, Juantok C, et al. Time course of endocrine changes in the hypothesis-gonad axis induced by hypobaric hypoxia in male rats. *J Reprod and Devt.*, 54, 1 (2008).
- [35] Romeo C, Ientile R, Impellizzeri P, Turiaco N, Teletta M, Antonuccio P. Preliminary report on nitric oxide-mediated oxidative damage in adolescent varicocele. *Hum Reprod.*, 18, 1 (2003).

- [36] Ozdamar AS, Soyulu AG, CulhaM, Ozden M, Gökalp A. Testicular oxidative stress. Effects of experimental varicocele in adolescent rats. Urol Int., 73, 4 (2004).
- [37] Zepeda A, Aguayo LG, Fuentealba J, Figueroa C, Acevedo A, Salgado P, et al. Blueberry extracts protect testis from hypobaric hypoxia induced oxidative stress in rats. Oxid Med Cell Longev., 975870 (2012).
- [38] Farías JG, Bustos-Obregón E, Reyes JG. Increase in testicular temperature and vascularization induced by hypobaric hypoxia in rats. J Androl, 26, 6 (2005).